Rickettsial Diseases 76

Lucas S. Blanton and David H. Walker

Chapter Contents

Spotted Fever and Typhus Group Rickettsial Infections 1333
Scrub Typhus 1340
Human Ehrlichioses 1340
Human Granulocytic Anaplasmosis 1341
Q Fever 1341

Key features

- Rickettsiae are small, obligately intracellular, Gram-negative bacteria that reside within an arthropod host (tick, flea, louse, or mite) during part of their life cycle
- The arthropod vector transmits the rickettsiae in its saliva or feces during feeding
- The major vertebrate target cells of *Rickettsia* (endothelium), *Orientia* (endothelium), *Ehrlichia* (monocytes or neutrophils), *Anaplasma* (neutrophils), and *Coxiella* (macrophages) determine to a large degree the pathogenesis of the disease
- In most spotted fever rickettsioses and scrub typhus, an eschar at the site of the vector's inoculation of organisms is an important physical sign
- A rash is the diagnostically critical clinical manifestation of Rocky Mountain spotted fever, other spotted fevers, murine typhus, and louse-borne typhus
- One of the most common rickettsial diseases in travelers is African tick bite fever

INTRODUCTION

Members of the order Rickettsiales are small, obligately intracellular, Gram-negative bacteria that reside within an arthropod host for at least part of their life cycle[1]. At least 30 bacterial species belonging to six genera (*Rickettsia, Orientia, Ehrlichia, Anaplasma, Neorickettsia, and Neoehrlichia*) as well as the related *Coxiella* genus in the order Legionellales are known agents of human diseases (Table 76.1). Cutaneous manifestations vary from nearly always present in some spotted fevers and typhus to rare in others, such as human granulocytic anaplasmosis and Q fever (Table 76.2). Clinical recognition of a rash is frequently the event that leads to appropriate antimicrobial treatment for life-threatening Rocky Mountain spotted fever (RMSF) and other rickettsioses.

SPOTTED FEVER AND TYPHUS GROUP RICKETTSIAL INFECTIONS

History

Epidemic typhus was described by Fracastorius in Italy in 1546; RMSF, by Maxey in Idaho in 1899; and boutonneuse fever by Conor in Tunisia in 1910. A rickettsial agent was first identified in 1906 in the Bitterroot Valley of western Montana by Howard Ricketts, who also recognized its transmission by ticks. In 1916, S. Burt Wolbach visualized this agent, later named *Rickettsia rickettsii*, within endothelial cells. Charles Nicolle discovered in 1909 that lice transmit epidemic typhus, which was subsequently found to be caused by *Rickettsia prowazekii*. Epidemic louse-borne typhus influenced the outcome of most European wars after 1500, including Napoleon's failed Russian invasion in 1812 and World War I, during and after which typhus affected 25 million persons and caused 3 million deaths in Russia. In 1934, recrudescent typhus (Brill–Zinsser disease) was determined to be caused by reactivation of latent *R. prowazekii* infection. Endemic or murine typhus was shown during the 1930s to have a rat reservoir and flea vector.

Epidemiology

Spotted fever group rickettsiae (SFGR) are maintained in nature principally via transmission of the bacteria in infected ova from one generation of tick, mite, or flea to the next (see Table 76.1; Fig. 76.1). During feeding, infected arthropods instill saliva containing rickettsiae into their host's skin. Thus, the seasonal and geographic distribution of each disease (Fig. 76.2) depends upon the range and the host-seeking activity



Fig. 76.1 Comparison of *Ixodes scapularis* (blacklegged tick), *Amblyomma americanum* (lone star tick), and *Dermacentor variabilis* (American dog tick), by life stage. *From Chapman AS, et al. MMWR Recomm Rep 2006;55:1–27.*

Downloaded for Anonymous User (n/a) at Egyptian Knowledge Bank from ClinicalKey.com by Elsevier on March 10, 2024. For personal use only. No other uses without permission. Copyright ©2024. Elsevier Inc. All rights reserved.

EPIDEMIOLOGY OF RICKETTSIAL AND RELATED INFECTIONS			
Agent	**Disease**	**Transmission**	**Geographic distribution**
Rickettsia rickettsii	Rocky Mountain spotted fever, Brazilian spotted fever	**Bite of tick:**	
		Dermacentor variabilis (Fig. 76.1)	Eastern two-thirds > Pacific Coast of US
		D. andersoni	Rocky Mountain states
		Rhipicephalus sanguineus	Southwestern US; northern Mexico
		Amblyomma cajennense complex, *A. aureolatum*	Mexico; Central and South America
Rickettsia akari	Rickettsialpox	**Bite of mouse mite**:	
		Liponyssoides sanguineus	North America; Eurasia
Rickettsia conorii (4 subspecies)	Boutonneuse fever (Mediterranean spotted fever), Indian and Israeli tick typhus, Astrakhan spotted fever	**Bite of tick**:	
		Rhipicephalus sanguineus	Southern Europe; Africa; western and southern Asia
		Rh. pumilio	Southern Russia
Rickettsia sibirica	North Asian and Siberian tick typhus, lymphangitis-associated rickettsiosis	**Bite of tick**:	
		Dermacentor nuttallii, D. silvarum, Haemaphysalis concinna, Hyalomma asiaticum, others	Eurasia and Africa
Rickettsia heilongjiangensis	Far Eastern spotted fever	**Bite of tick:**	
		Haemaphysalis species, D. silvarum, others	Eastern Russia, China, Thailand, Japan
Rickettsia australis	Queensland tick typhus	**Bite of tick**:	
		Ixodes cornuatus, I. holocyclus, I. tasmani	Eastern Australia
Rickettsia honei	Flinders Island spotted fever	**Bite of tick**:	
		Bothriocroton hydrosauri, others	Australia and Nepal (Flinders Island is located between Tasmania and mainland Australia)
Rickettsia japonica	Japanese spotted fever	**Bite of tick**:	
		Haemaphysalis flava, H. longicornis, Ixodes ovatus, Dermacentor taiwanensis	Japan and eastern Asia
Rickettsia massiliae	*Rickettsia massiliae* rickettsiosis	**Bite of tick:**	
		Rhipicephalus species, others	Europe, South America, Africa, Asia
Rickettsia felis	Flea-borne spotted fever	**By flea:**	
		e.g. *Ctenocephalides felis*	Worldwide
Rickettsia africae	African tick bite fever	**Bite of tick:**	
		Amblyomma hebraeum	Southern Africa
		A. variegatum	Central, eastern, and western Africa; Caribbean islands
Rickettsia parkeri	*Rickettsia parkeri* rickettsiosis (maculatum disease, American tick bite fever)	**Bite of tick:**	
		Amblyomma maculatum, A. americanum, Dermacentor parumapertus	North America
		A. triste, A. tigrinum, A. ovale	South America
Rickettsia philipii (364D)	Pacific Coast tick fever	**Bite of tick:**	
		Dermacentor occidentalis	California
Rickettsia aeschlimannii	*Rickettsia aeschlimannii* infection	**Bite of tick**:	
		Haemaphysalis concinna, Hyalomma marginatum, Rhipicephalus turanicus, others	Africa, Asia, Europe
Rickettsia slovaca, Rickettsia raoultii, or *Candidatus* Rickettsia rioja	Tick-borne lymphadenopathy, Dermacentor-borne necrosis and lymphadenopathy (DEBONEL)	**Bite of tick** (usually on the scalp):	
		Dermacentor marginatus, D. reticularis, others	Europe
Rickettsia prowazekii	Epidemic louse-borne typhus	**Feces of human body louse** (*Pediculus humanus* var. *corporis*)	South America; Africa; Eurasia
	Brill–Zinsser disease	**None (recrudescence of latent infection)**	
	Flying squirrel typhus	**Contact with flying squirrel** (*Glaucomys volans*) and its fleas and lice	North America
Rickettsia typhi	Murine (endemic) typhus	**Feces of fleas**:	
		Xenopsylla cheopis	Worldwide
		Ctenocephalides felis	North America

Table 76.1 Epidemiology of rickettsial and related infections.

Downloaded for Anonymous User (n/a) at Egyptian Knowledge Bank from ClinicalKey.com by Elsevier on March 10, 2024. For personal use only. No other uses without permission. Copyright ©2024. Elsevier Inc. All rights reserved.

EPIDEMIOLOGY OF RICKETTSIAL AND RELATED INFECTIONS			
Agent	**Disease**	**Transmission**	**Geographic distribution**
*Orientia tsutsugamushi**	Scrub typhus	**Bite of larval trombiculid mites**:	
		L. deliense, L. fletcheri, L. scutellare, L. arenicola	Southern and eastern Asia; islands of the southwestern Pacific and Indian Oceans; northern Australia
		e.g. *L. pallidum*	Japan; Korea; Russian Far East
		e.g. *L. scutellare*	China; Malaysia
		e.g. *L. deliense, L. fletcheri, L. arenicola*	Tropical regions
Ehrlichia chaffeensis	Human monocytic ehrlichiosis	**Bite of tick**:	
		Amblyomma americanum (Fig. 76.1), *Dermacentor variabilis*	Southeastern and South Central US
Ehrlichia muris eauclairensis	Ehrlichiosis (due to *Ehrlichia muris eauclairensis*)	**Bite of tick:**	
		Ixodes scapularis	Upper midwestern US
Ehrlichia ewingii	Ehrlichiosis (due to *Ehrlichia ewingii*)	**Bite of tick:**	
		Amblyomma americanum	Southeastern and South Central US
Anaplasma phagocytophilum	Human granulocytic anaplasmosis	**Bite of tick:**	
		Ixodes scapularis (Fig. 76.1)	Northern US
		I. pacificus	Far western US
		I. ricinus, I. persulcatus	Eurasia
Candidatus Neoehrlichia mikurensis	Neoehrlichiosis†	**Bite of tick:**	
		Ixodes ricinus	Europe
		Ixodes persulcatus	East Asia
Neorickettsia sennetsu	Sennetsu fever‡	**Ingestion** of infected trematode-infested raw fish or fish paste	East Asia
Coxiella burnetii	Q fever	**Aerosol** of infected products of parturition of ruminants (e.g. sheep, cattle, goats), cats, and other animals¶	Worldwide

*More recently identified causes of scrub typhus include *Orientia chuto* (Dubai, Africa) and *Candidatus* Orientia chiloensis (Chile).
†Febrile illness that may be associated with thrombosis, thrombophlebitis, and arteritis; described primarily in immunocompromised patients with a hematologic malignancy or autoimmune disease.
‡Mononucleosis-like syndrome characterized by fever, malaise, and generalized lymphadenopathy.
¶Less common means of transmission include ingestion of contaminated dairy products and tick bites (e.g. *Dermacentor* spp.).

Table 76.1 Epidemiology of rickettsial and related infections. Additional agents that have been implicated in infections with eschar and/or rash include *Rickettsia monacensis* (Europe) and *Candidatus* Rickettsia tarasevichiae (China). *Rickettsia helvetica* transmitted by *Ixodes ricinus* in Europe can also lead to "aneruptive fever" that lacks cutaneous involvement.

of the particular vector. For example, RMSF usually occurs during tick season, from late spring until the end of summer[2].

Typhus group rickettsiae are deposited on the host's skin in the feces of feeding human body lice (*R. prowazekii*) or fleas (*R. typhi*). The organisms are subsequently scratched into the skin, rubbed into mucous membranes, or inhaled. Humans who recover from louse-borne typhus remain latently infected and years later may develop recrudescent illness (Brill–Zinsser disease) and associated rickettsemia. Such individuals can infect feeding lice, which may then spread the disease to another person and ignite an epidemic. In addition, a zoonotic cycle of *R. prowazekii* is maintained in flying squirrels and their fleas and lice. *R. typhi* is maintained in natural cycles, classically in rats and oriental rat fleas as well as in opossums and cat fleas. Murine (endemic) typhus caused by *R. typhi* is prevalent in tropical and subtropical coastal regions worldwide, representing an increasingly recognized cause of febrile illness in travelers[3].

Pathogenesis

After entry into the dermis, rickettsiae spread throughout the body via the bloodstream. They attach to vascular endothelial cells by outer membrane protein B and, in the case of SFGR, also via outer membrane protein A. The organisms enter the cells by induced phagocytosis and then escape from the phagosome into the cytosol, where they obtain amino acids, nucleotides, and other building blocks for growth from the host cell and divide by binary fission. SFGR move intra- and intercellularly by stimulating propulsion via the host cell's actin, resulting

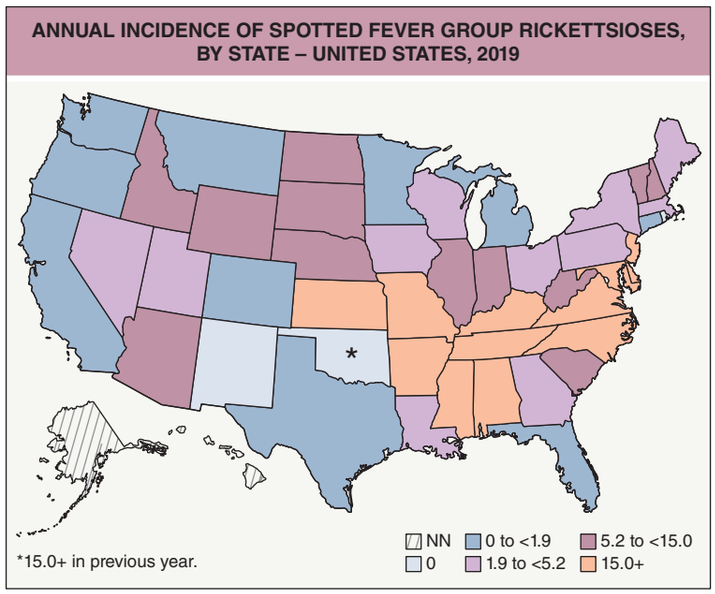

Fig. 76.2 Annual incidence (per million persons) of spotted fever group rickettsioses, by state – United States, 2019. Because serologic tests cannot reliably distinguish among spotted fever group *Rickettsia* species, since 2010 CDC reporting has combined them in a category that includes Rocky Mountain spotted fever (RMSF), *Rickettsia parkeri* rickettsiosis, Pacific Coast tick fever, and rickettsialpox. NN, not notifiable. *Courtesy US Centers for Disease Control and Prevention, cdc.gov/rmsf/stats/index.html.*

Downloaded for Anonymous User (n/a) at Egyptian Knowledge Bank from ClinicalKey.com by Elsevier on March 10, 2024. For personal use only. No other uses without permission. Copyright ©2024. Elsevier Inc. All rights reserved.

DERMATOLOGIC MANIFESTATIONS OF RICKETTSIAL INFECTIONS				
Disease	**Rash incidence (%)**	**Appearance of rash after onset of illness**	**Characteristics**	**Eschar (%)**
Rocky Mountain spotted fever, Brazilian spotted fever	90	3–5 days	Early macules, later papules; petechiae in 50% of patients; retiform purpura in severe disease	<1
Rickettsialpox	100	2–3 days	Early macules and papules; later papulovesicles and crusts	90
Boutonneuse fever and related conditions	95	3–5 days	Early macules, later papules	50
North Asian tick typhus and related conditions	100	4–5 days	Macules and papules	75
Far Eastern spotted fever	90	3–4 days	Macules and papules	90
Queensland tick typhus	90	2–6 days	Macules, papules, and vesicles	75
Flinders Island spotted fever	85	A few days	Early macules and papules, later (in some patients) petechiae	50
Japanese spotted fever	100	A few days	Early macules, later (in some patients) petechiae	90
Rickettsia massiliae rickettsiosis	75	Not reported	Macules and papules	100
Flea-borne spotted fever	80	A few days	Macules and papules; occasionally pustules	15–20
African tick bite fever	50	2–5 days	Generally relatively few lesions; macules, often vesicles	90, often multiple
Rickettsia parkeri rickettsiosis	80	2–4 days	Macules, papules, often vesicles	100
Pacific Coast tick fever	15	Not reported	Macules in region of eschar (one patient)	100
R. aeschlimannii infection	50	Not known	Macules and papules	100
Tick-borne lymphadenopathy	5	Not reported	Macules and papules	100
Epidemic louse-borne typhus	50–100	4–5 days	Early macules, later papules; petechiae	None
Brill–Zinsser disease	50	4–6 days	Macules and papules	None
Flying squirrel typhus	65	2–8 days	Macules and papules	None
Murine (endemic) typhus	50	5 days	Early macules, later papules	None
Scrub typhus	50	4–6 days	Early macules, later papules	60–90
Human monocytic ehrlichiosis	40	Median, 5 days	Macules, papules, occasionally petechiae	None
Ehrlichia muris eauclairensis ehrlichiosis	10	Not reported	Not reported	None
Human granulocytic anaplasmosis	≤5	Not reported	Erythematous rash on neck/chest; petechiae or purpura	None
Neoehrlichiosis	Rare	Not reported	Erythematous macules, erythema nodosum	None
Sennetsu fever	Rare	Not reported	Diffuse erythema, petechiae	None
Q fever	Rare	Associated with chronic infection	Macules, papules, palpable purpura; rarely erythema nodosum	None

Table 76.2 Dermatologic manifestations of rickettsial and related infections. To date, skin findings have not been described in patients with *Ehrlichia ewingii* ehrlichiosis.

in a contiguous network of infected endothelial cells that represent the source of the vascular-based disease manifestations, including skin lesions. Whereas SFGR injure the host endothelium by stimulating these cells to produce toxic reactive oxygen species, typhus group rickettsiae replicate within the infected endothelial cells until they burst[4].

The major pathophysiologic effect of rickettsial infection is increased vascular permeability, which can result in edema, hypovolemia, and hypotension. Although endothelial cells of the microcirculation are infected in every organ, the critical target organs in life-threatening infections are the lung and brain. A fatal outcome can result if increased vascular permeability leads to non-cardiogenic pulmonary edema, acute respiratory distress syndrome (ARDS), and meningoencephalitis[2].

As the infection progresses, macrophages and lymphocytes infiltrate the walls of affected vessels and act as effector cells, secreting cytokines such as interferon-γ and tumor necrosis factor. Infected endothelial cells and macrophages themselves are activated by cytokines, resulting in killing of intracellular rickettsiae by mechanisms involving nitric oxide, reactive oxygen species, and tryptophan starvation (via enzymatic degradation of this amino acid). Recruited cytotoxic T cells are critical to the apoptotic elimination of infected endothelial cells, which occurs through perforin-dependent pathways. A combination of rickettsicidal mechanisms and killing of infected endothelial cells ultimately leads to clearance of the infection. Antibodies to rickettsiae play a role in the prevention of reinfection[4].

Clinical Features

Clinical course and systemic features

Rickettsial infections typically begin with fever (>102°F [39°C]) in two-thirds of patients during the first 3 days of the illness and in 90% thereafter, accompanied by a severe headache and myalgias. Nausea, vomiting, abdominal pain, and abdominal tenderness are also frequent early symptoms. When a rash develops, it usually appears on day 3–6 of the illness (see below and Table 76.2). Cough (related to pneumonitis and/or pulmonary edema) and confusion or lethargy (related to encephalitis) may represent additional symptoms. Patients often have thrombocytopenia, although full-blown disseminated intravascular coagulation is rare, and hyponatremia frequently occurs secondary to increased antidiuretic hormone secretion in response to hypovolemia. Additional laboratory findings may include anemia, elevated liver enzymes, and abnormal renal function tests. As the clinical course progresses, hypotension, acute kidney injury, respiratory failure, and coma may develop[5].

Severe rickettsioses continue to cause death due to misdiagnosis and/or *delayed initiation* of antirickettsial treatment, with approximate mortality rates as follows: 4% for RMSF and louse-borne typhus; 2.5% for boutonneuse fever; and 0.5% for murine typhus[3]. If *not treated* with an appropriate antimicrobial agent, ~25% and 15% of patients with RMSF and louse-borne typhus, respectively, will die[2,6]. The case fatality rate is higher with older age, male sex, and comorbidities.

Downloaded for Anonymous User (n/a) at Egyptian Knowledge Bank from ClinicalKey.com by Elsevier on March 10, 2024. For personal use only. No other uses without permission. Copyright ©2024. Elsevier Inc. All rights reserved.

Fig. 76.3 Rocky Mountain spotted fever. The cutaneous lesions often appear first on the wrists and ankles. *Courtesy Philippe Berbis, MD.*

Fig. 76.4 Rocky Mountain spotted fever. Petechiae on the palms and soles often develop relatively late in the disease course. *Courtesy Ronald P. Rapini, MD.*

Fig. 76.5 Rocky Mountain spotted fever. Petechiae are present within erythematous papules and plaques on the buttocks. Some of the lesions have a retiform pattern.

Fig. 76.6 Rocky Mountain spotted fever. Retiform purpura on the distal lower extremity in a patient with more severe disease.

Shared cutaneous features

In many types of spotted fevers other than RMSF (see Table 76.2), an eschar consisting of central dermal and epidermal necrosis (typically 0.5–2 cm in diameter) surrounded by a zone of erythema appears during the incubation period (usually 4–10 days prior to onset of the illness) (see Figs. 76.7 and 76.8A). This represents the site of inoculation of rickettsiae by the tick or mite[7,8]. The rash typically begins as erythematous macules around the wrists and ankles (spotted fevers) (Fig. 76.3) or axillae (typhus fevers). The exanthem evolves during the course of the illness, with lesions eventually appearing on most of the body, often with relative sparing of the face. Macules and papules develop on the palms and soles in approximately half of the patients with spotted fevers, often relatively late in the disease course (Fig. 76.4). Macules reflect vasodilation related to infection of endothelial cells in the dermal microcirculation. As perivascular edema develops secondary to leakage of fluid from damaged blood vessels, macules become papules. When endothelial cell destruction leads to more severe vascular injury, petechiae appear within the lesions (Fig. 76.5), which can coalesce and become purpuric (Fig. 76.6). Cutaneous necrosis, including gangrene of the digits, extremities, ears or prepuce, occurs in ~5% of patients with RMSF and occasionally in epidemic typhus; this is due to more severe infection of the microcirculation in acral sites, which are cooler and therefore more favorable for rickettsial growth.

Features of specific diseases

RMSF usually follows the classic clinical course described above. After an incubation period of 2–14 (mean, 7) days following the tick bite (which ~40% of patients do not recall), affected individuals present with fever, myalgias, headache, and in >50% of patients, gastrointestinal symptoms. The rash typically appears 3–5 days after onset of the illness as subtle erythematous macules on the wrists and ankles, which is followed by centripetal spread to the trunk, formation of papular lesions, and eventual development of petechiae (~50% of patients). However, cutaneous findings are absent in 10%–15% of patients and may be difficult to recognize in darkly pigmented skin.

R. parkeri and *R. africae*, closely related strains of SFGR, cause two similar infections, ***R. parkeri rickettsiosis*** and ***African tick bite fever***, respectively. The former is endemic in the south central and southeastern US (the range of *A. maculatum*, the Gulf Coast tick; see Table 76.1 & Fig. 76.12B) as well as in South America, while the latter is endemic in sub-Saharan Africa and represents the rickettsial disease with the highest incidence among all international travelers returning to the US or other countries worldwide[9,10]. Patients with these conditions typically present with mild constitutional symptoms (e.g. fever, headache, myalgias), one or more eschars (Fig. 76.7), and tender lymphadenopathy in the region draining the eschar(s). In 50%–80% of affected individuals, usually 2–4 days after disease onset, a rash develops on

Downloaded for Anonymous User (n/a) at Egyptian Knowledge Bank from ClinicalKey.com by Elsevier on March 10, 2024. For personal use only. No other uses without permission. Copyright ©2024. Elsevier Inc. All rights reserved.

Fig. 76.7 African tick bite fever. Eschar at the tick bite site.

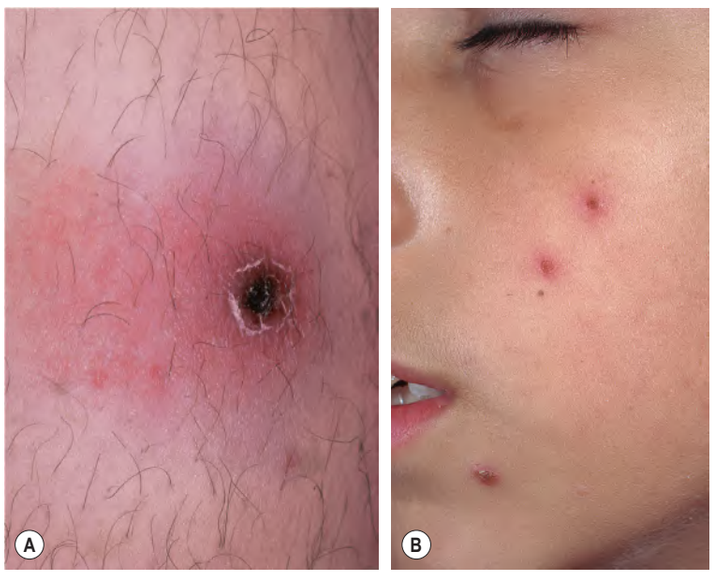

Fig. 76.8 Rickettsialpox. A Eschar at the site of the mite bite. **B** Scattered papules with hemorrhagic crusts.

the trunk and extremities, sometimes involving the palms and soles. The eruption may be relatively sparse and often features small central vesicles or pustules within erythematous macules and papules. No deaths have been reported for either type of infection. Despite the substantial difference in severity, it is likely that many *R. parkeri* infections are misdiagnosed as RMSF owing to serologic cross-reactivity with *R. rickettsii*[10].

Rickettsialpox occurs primarily in urban areas, especially in the northeastern US, and is transmitted by mites that parasitize house mice. A papulovesicle arises within 48 hours at the site of a mite bite and eventuates in an eschar with surrounding erythema and induration (Fig. 76.8A). Constitutional symptoms (e.g. fever, headache, myalgias) begin 1 to 2 weeks later, followed in 2 to 3 days by a cutaneous eruption that often involves the face (Fig. 76.8B) as well as the trunk and extremities, in no particular sequence. Approximately 20–40 skin lesions typically develop, evolving from erythematous macules and papules to papulovesicles to hemorrhagic crusts. The palms and soles are occasionally affected, and an enanthem characterized by small erosions on the tongue, palate, and pharynx may occur[3].

Pathology

Rickettsial infection is multifocal, which is reflected in the scattered distribution of cutaneous lesions. Randomly obtained tissue samples are unlikely to contain the classic finding of a lymphocytic vasculitis with extravasation of erythrocytes (Fig. 76.9), which is typically present in the center of a petechial macule or papule. The early finding of perivascular edema is difficult to identify histopathologically because of formalin-associated tissue shrinkage. Small fibrin thrombi are

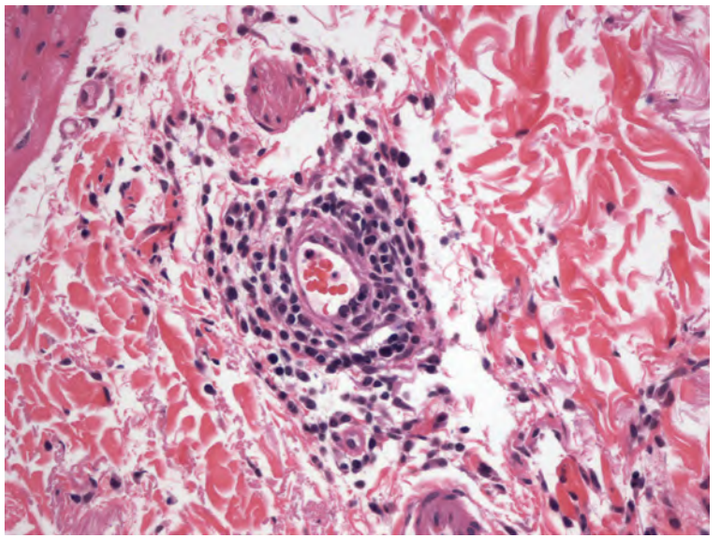

Fig. 76.9 Histologic findings in Rocky Mountain spotted fever. Typical lymphohistiocytic vasculitis involving a dermal blood vessel. *Courtesy James W. Patterson, MD.*

evident in a minority of cases. Later in the disease course, leukocytoclastic vasculitis can be detected histopathologically in the skin and other organs. Eschars reflect coagulative necrosis of the epidermis. Skin lesions of rickettsialpox show subepidermal edema associated with a mild vasculitis and dense lymphohistiocytic infiltrate. Fibrin thrombi may be observed.

Diagnosis and Differential Diagnosis

The diagnosis of rickettsiosis is based on disease signs and symptoms as well as potential arthropod exposure (Fig. 76.10)[11]. It is essential to begin empiric treatment with effective antirickettsial agents based on clinical suspicion rather than awaiting laboratory confirmation. Indeed, serologic diagnosis is usually retrospective, because antibodies do not develop until day 7 of the illness or later. Serologic confirmation requires seroconversion or a 4-fold increase between acute and convalescent antibody titers[12]. Previous exposure to non- or mildly pathogenic cross-reacting SFGR (e.g. *Rickettsia amblyommatis* within *Amblyomma americanum* [lone star] ticks) can make interpretation of single serologic specimens difficult[12,13].

Circulating rickettsiae are generally too few early in the illness to be detected in the blood by PCR-based assays, whereas PCR analysis of fresh and even formalin-fixed skin biopsy specimens is more sensitive[14] (see Fig. 76.10). Rickettsiae can also be identified by immunofluorescence or immunohistochemistry in a biopsy specimen of an eschar or a maculopapular lesion (Fig. 76.11), especially if the latter is petechial.

Prior to the onset of the rash, the differential diagnosis may include a wide variety of viral infections, ehrlichiosis, and typhoid fever. Patients with prominent nausea and vomiting are often suspected to have viral or bacterial enterocolitis. Abdominal pain and tenderness can suggest an acute surgical abdomen, which has led to exploratory laparotomies. Cough and crackles on auscultation due to pulmonary edema may lead to suspicion of bacterial or viral pneumonia. Neurologic signs and cerebrospinal fluid pleocytosis can suggest viral or bacterial meningoencephalitis, while jaundice and elevated hepatic enzymes may prompt the consideration of viral hepatitis or leptospirosis.

When the cutaneous eruption initially develops, the differential diagnosis may include a viral exanthem, a drug eruption, ehrlichiosis, Kawasaki disease, and early secondary syphilis. Exanthems due to enteroviruses, Epstein–Barr virus, parvovirus B19, adenovirus, dengue fever, and measles may have a petechial component (see Fig. 81.2). When petechial and/or purpuric lesions become more prominent, meningococcemia, small vessel vasculitis, disseminated gonococcal infection, and viral hemorrhagic fevers (e.g. dengue; see Table 81.7) may also be considered. In patients with thrombocytopenia, immune thrombocytopenic purpura or thrombotic thrombocytopenic purpura represent additional possibilities. The differential diagnosis for rickettsialpox and other rickettsial eruptions with a vesicular component

Downloaded for Anonymous User (n/a) at Egyptian Knowledge Bank from ClinicalKey.com by Elsevier on March 10, 2024. For personal use only. No other uses without permission. Copyright ©2024. Elsevier Inc. All rights reserved.

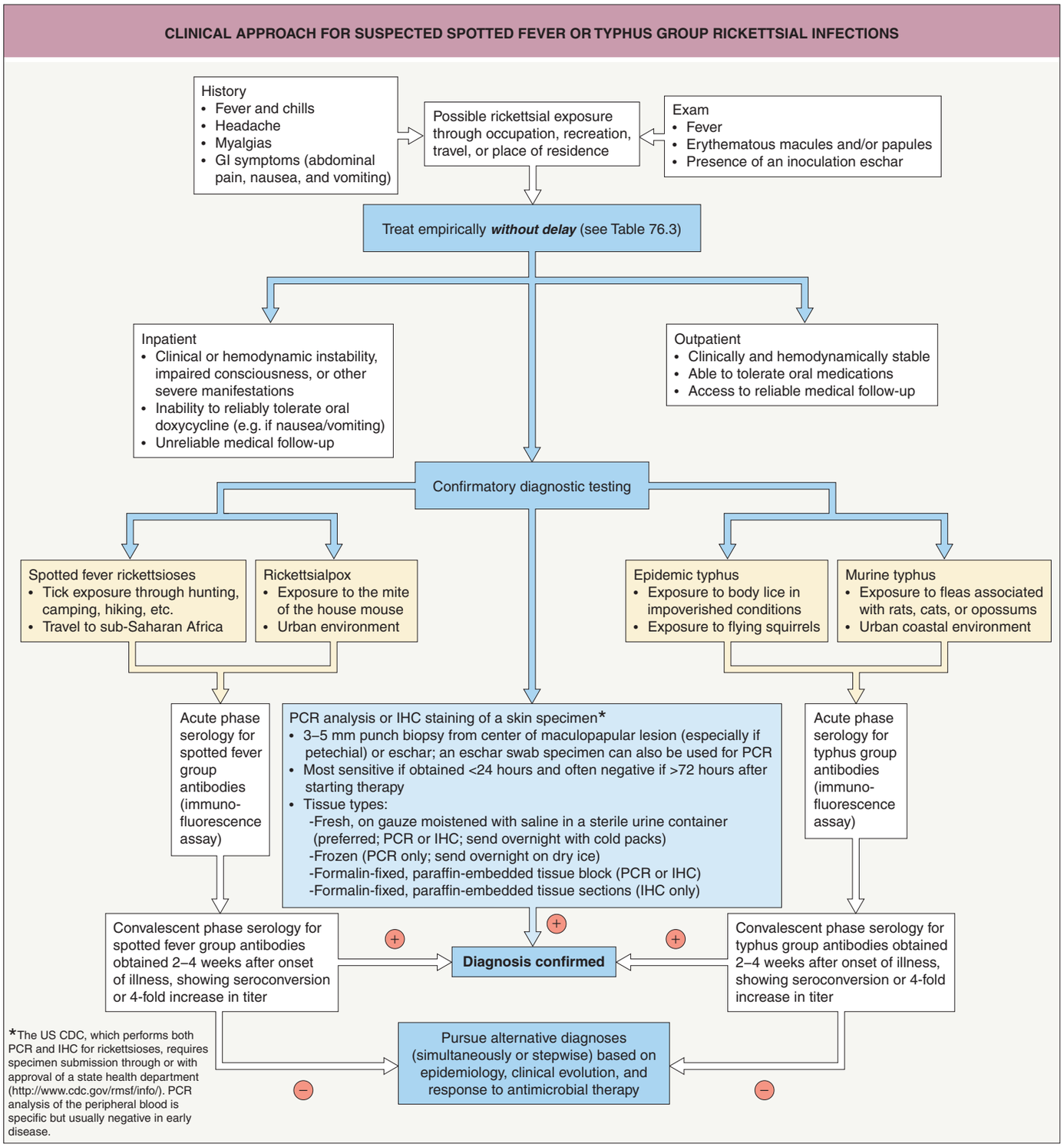

Fig. 76.10 Clinical approach for suspected spotted fever or typhus group rickettsial infections. IHC, immunohistochemical.

may include vesicular viral exanthems (e.g. due to coxsackieviruses), varicella, disseminated HSV infection, pityriasis lichenoides et varioliformis acuta (PLEVA), drug eruptions, bullous insect bite reactions, and scabies. Cutaneous necrosis resembling an eschar can be seen in spider bites, ecthyma gangrenosum (typically in immunocompromised hosts), cutaneous anthrax, *Bacillus cereus* infection, cutaneous diphtheria, tularemia, scrub typhus (see below), and primary syphilis.

Treatment

The drug of choice for rickettsial infections in nearly all patients, including young children, is doxycycline[11] (Table 76.3). Chloramphenicol is a less effective alternative, having a higher rate of fatal outcomes; in the US, oral chloramphenicol is not available and the intravenous form is difficult to obtain. Although older tetracyclines may lead to adverse effects in pregnant women and the developing fetus, doxycycline appears to be relatively safe and represents the best treatment option for severe rickettsioses (e.g. RMSF) during pregnancy[11].

Mild cases of boutonneuse fever in children have been treated with azithromycin or clarithromycin with an outcome equivalent to treatment with chloramphenicol. These antibiotics may also represent therapeutic options for mild rickettsioses during pregnancy[15]. Although fluoroquinolones have been used successfully to treat patients with boutonneuse fever, worse outcomes have been noted in those with

Downloaded for Anonymous User (n/a) at Egyptian Knowledge Bank from ClinicalKey.com by Elsevier on March 10, 2024. For personal use only. No other uses without permission. Copyright ©2024. Elsevier Inc. All rights reserved.

severe disease[16]. Fluoroquinolone or azithromycin therapy also results in delayed defervescence as compared to tetracyclines in murine typhus[3,17]. Therefore, treatment of severe rickettsial infection with macrolides or fluoroquinolones is not recommended.

SCRUB TYPHUS

Scrub typhus was described in association with red mites in China in CE 313. *Orientia tsutsugamushi* was discovered in Japan by Nagayo and Ogata in the 1920s and early 1930s. There are >70 strains of *O. tsutsugamushi*, which differs from *Rickettsia* spp. in its cell wall proteins and ultrastructure as well as by lacking lipopolysaccharide. *O. tsutsugamushi* is maintained in nature via transovarial transmission by its vector, trombiculid mites (see Table 76.1). Eggs laid by infected mites hatch with the emergence of infected larvae (chiggers) that feed on rats.

Approximately one million cases of scrub typhus occur annually, primarily affecting rural populations in Asia (from Afghanistan to Japan) and northern Australia[18]. In addition, novel *Orientia* spp. have been implicated in scrub typhus occurring in Dubai and Africa (*O. chuto*) as well as Chile (*Candidatus* O. chiloensis)[19–21]. Immunity is strain-specific and transient, resulting in reinfections. The severity of the illness is age-dependent and varies geographically.

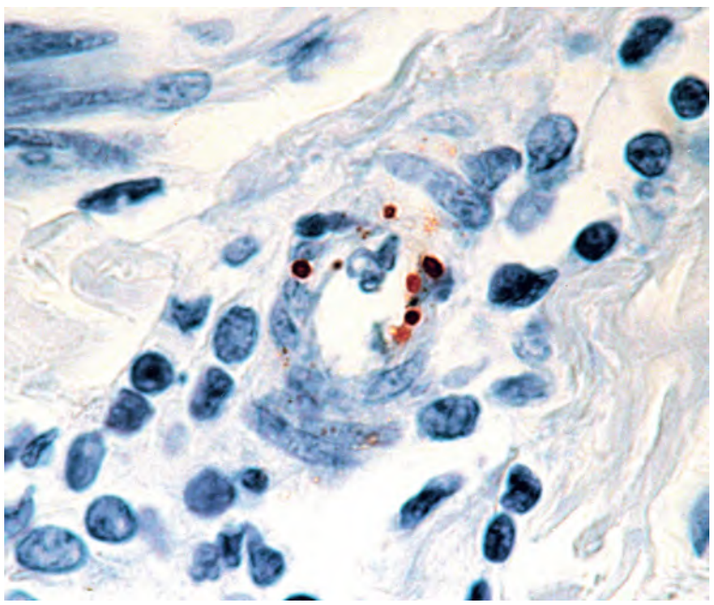

Fig. 76.11 Immunohistochemical detection of spotted fever rickettsiae. Organisms within the endothelium of a dermal blood vessel are highlighted by brown staining.

A cutaneous eschar forms at the site of chigger feeding in 60%–90% of primary infections. This is followed by regional lymphadenopathy, fever, and headache; generalized lymphadenopathy, conjunctival hyperemia, and hearing loss may also develop[18]. A rash occurs in approximately half of patients, usually appearing as erythematous macules on the trunk 4–6 days after disease onset. Lesions then become papular, with subsequent centrifugal spread. Interstitial pneumonia occurs frequently, presenting with cough, tachypnea, and radiographic infiltrates; meningoencephalitis is a less common manifestation[22]. In severe cases, ARDS, acute kidney injury, and hypotensive shock may develop.

Tetracyclines, particularly doxycycline, are generally the first-line treatment for scrub typhus. Azithromycin has similar efficacy and represents an option for pregnant women and children, whereas chloramphenicol is less effective[15]. However, reduced responsiveness of *O. tsutsugamushi* infections to doxycycline and chloramphenicol treatment has been reported in northern Thailand[23,24], and patients there have been treated successfully with azithromycin or rifampin.

HUMAN EHRLICHIOSES

Ehrlichial infections have been well known to veterinarians for >75 years, but human infection was not recognized until 1987, when an organism eventually identified as *Ehrlichia chaffeensis* was implicated as the etiologic agent of human monocytic ehrlichiosis (HME)[25]. In 1999, *E. ewingii* was found to cause human infections (most often in immunosuppressed patients) with clinical manifestations similar to HME[26]. *Ehrlichia* spp. are obligately intracellular, Gram-negative bacteria that target monocytes/macrophages (*E. chaffeensis*) or neutrophils (*E. ewingii*), within which they reside as a cytoplasmic microcolony that is occasionally visible in a peripheral blood smear. Both agents are maintained in a zoonotic cycle involving persistently infected white-tailed deer as the major reservoir and *Amblyomma americanum* as the primary vector (see Table 76.1). These ticks were originally found primarily in the south central and southeastern US, but their geographic distribution has expanded into the upper midwestern and northeastern states, overlapping with that of *Ixodes scapularis* (Fig. 76.12A)[25]. Trends of increasing temperatures with climate change are predicted to continue to shift the ranges of tick species northward[27]. *Ehrlichia muris eauclairensis*, transmitted by *Ixodes scapularis*, causes a human infection similar to HME in the upper midwestern US[28].

HME is a serious infectious disease with a ~3% case fatality rate. Its incidence is likely underestimated due to the lack of specific clinical findings[29]. Patients with HME and *Ehrlichia ewingii* ehrlichiosis typically present with fever, headache, and myalgias; common laboratory abnormalities include thrombocytopenia, leukopenia, and elevated transaminases. Progression to ARDS, meningoencephalitis, and toxic shock syndrome-like manifestations can occur. In addition, overwhelming ehrlichial infection may develop in immunocompromised hosts, such as those with HIV infection and organ transplant recipients[29,30].

TREATMENT OF RICKETTSIAL AND RELATED DISEASES Rx

	Medication	Adult dose	Pediatric dose	Treatment duration
• First choice for virtually all rickettsial infections in children and adults*	Doxycycline	100 mg po or iv twice daily	2.2 mg/kg (max. 100 mg) po or iv twice daily	Until ≥3 days after defervescence, for a minimum total course of 5–7 days
• Alternative for non-life-threatening HME or HGA in pregnant women • Alternative for scrub typhus	Rifampin	300 mg po twice daily	10 mg/kg (max. 300 mg) twice daily	Until ≥3 days after defervescence, for a minimum total course of 7–10 days
• First choice for scrub typhus in pregnant women and potentially children • Alternative for mild rickettsioses (e.g. early boutonneuse fever) during pregnancy or in children	Azithromycin†	500 mg po daily	10 mg/kg po daily	3 days

*Other tetracyclines are also effective for rickettsial infection, but doxycycline is preferred during pregnancy, as older tetracyclines have been associated with adverse effects in this population (e.g. maternal pancreatitis, hepatitis, bone abnormalities in the developing fetus).
†Clarithromycin may also be considered.

Table 76.3 Treatment of rickettsial and related diseases. Empiric treatment with an appropriate agent should be initiated immediately when a diagnosis of Rocky Mountain spotted fever (RMSF), human monocytic ehrlichiosis (HME), human granulocytic anaplasmosis (HGA), or another potentially severe rickettsiosis is suspected clinically. Use of chloramphenicol in pregnant women is no longer recommended due to an increased likelihood of death in severe rickettsioses (e.g. RMSF) and potential risks including aplastic anemia and (when used in the late third trimester) gray baby syndrome. iv, intravenously; po, orally.

Downloaded for Anonymous User (n/a) at Egyptian Knowledge Bank from ClinicalKey.com by Elsevier on March 10, 2024. For personal use only. No other uses without permission. Copyright ©2024. Elsevier Inc. All rights reserved.

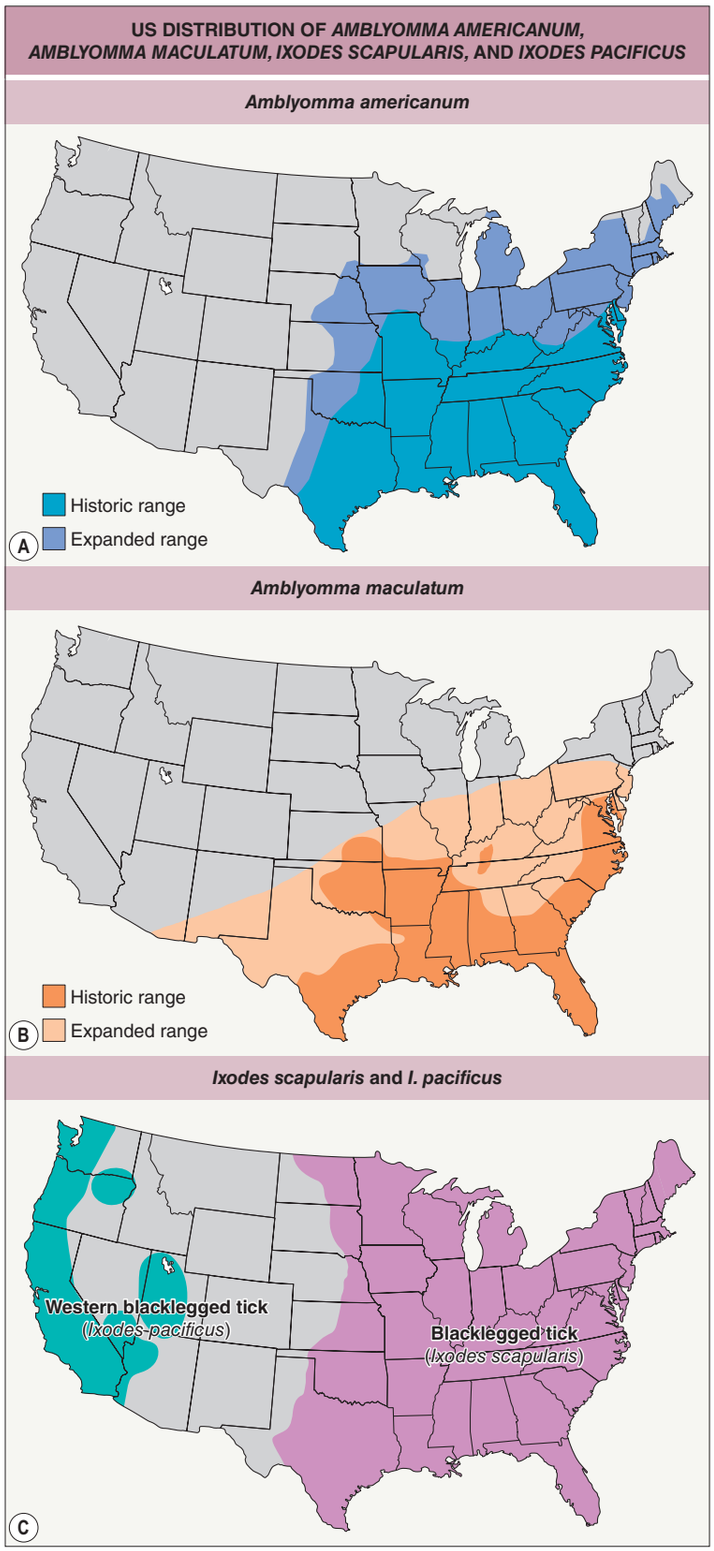

Fig. 76.12 US distribution of *Amblyomma americanum, A. maculatum, Ixodes scapularis*, and *I. pacificus*. *Amblyomma americanum* (**A**) and *A. maculatum* (Gulf Coast tick; **B**); both have original as well as extended distributions, with the latter in a second shade. **C** *Ixodes scapularis* and *I. pacificus*.

CUTANEOUS MANIFESTATIONS OF HUMAN MONOCYTIC EHRLICHIOSIS
Macular or maculopapular exanthematous eruptions
Mottled or diffuse macular erythema (transient or persistent)
Petechiae (favor the palms, soles, trunk, and palate)
Vesicles
Edema (especially of hands, feet, and scrotum)
Purpuric papules (with histologic evidence of vasculitis)
Nodules secondary to polyarteritis nodosa
Ulceration (reported on the penis)

Table 76.4 Cutaneous manifestations of human monocytic ehrlichiosis. Several types of lesions may be present simultaneously or sequentially in an individual patient.

Approximately 30%–40% of patients with HME have cutaneous manifestations, which develop a median of 5 days after the onset of the illness and may be more common in children[31]. Macular, maculopapular, and petechial eruptions involving the trunk and extremities are most often observed, but the morphology and distribution of skin lesions can vary considerably[31,32] (Table 76.4). *Ehrlichia ewingii* ehrlichiosis has not been reported to have cutaneous manifestations[26]. The differential diagnosis of ehrlichioses is similar to that of rickettsioses (see above).

Since *Ehrlichia* spp. and *Anaplasma phagocytophilum* are found within circulating monocytes or neutrophils, PCR-based assays of peripheral blood samples have greater sensitivity than for rickettsial infections[33]. However, empiric treatment should be initiated based on clinical suspicion rather than awaiting laboratory confirmation. Doxycycline is the drug of choice. *In vitro* evidence suggests that chloramphenicol is not an effective therapy for these infections.

HUMAN GRANULOCYTIC ANAPLASMOSIS

Anaplasma phagocytophilum, previously referred to as the "human granulocytic ehrlichiosis (HGE) agent", is an obligately intracellular bacterium (closely related to *Ehrlichia* spp.) that causes human granulocytic anaplasmosis (HGA; formerly known as HGE). HGA occurs in the same geographic distribution as Lyme disease (and babesiosis) owing to their transmission by the same *Ixodes* spp. tick vectors (see Table 76.1 & Fig. 76.12C). The clinical features of HGA are similar to those of HME, but HGA has a lower case fatality rate (0.5%–1%), often presents with peripheral neuropathy (but rarely meningoencephalitis), and seldom (≤5% of patients) has dermatologic manifestations other than petechiae or purpura related to thrombocytopenia[34]. Interestingly, Sweet syndrome has been described in association with HGA. As for HME, the first-line treatment is doxycycline.

Q FEVER

Coxiella burnetii are obligately intracellular bacteria categorized in the order Legionellales. Although they reside within several tick species, these organisms are transmitted to humans primarily by inhalation of aerosols generated from the placenta and birth fluids of infected animals (see Table 76.1)[35]. The bacteria target macrophages, where they thrive in acidic phagolysosomes, and their resistance to heat, desiccation, and disinfectants allows them to survive in the environment.

Acute disease typically presents as a nonspecific febrile illness, with atypical pneumonia or granulomatous hepatitis occurring occasionally. Chronic Q fever most often manifests as "culture-negative" endocarditis affecting a previously damaged heart valve. Cutaneous manifestations of Q fever are rare (see Table 76.2). A truncal maculopapular rash, an urticarial eruption, erythema nodosum, palpable purpura, palatal petechiae, and vasculitis (reported in association with mixed cryoglobulinemia) have been described.

REFERENCES

1. Yu XJ, Walker DH, Family I. Rickettsiaceae. In: Brenner DJ, Kreig NR, Staley JT, editors. *Bergey's Manual of Systematic Bacteriology: Proteobacteria*. v. 2. 2nd ed. New York: Springer-Verlag; 2005: p. 96–116.
2. Walker DH. Rickettsiae and rickettsial infections: the current state of knowledge. *Clin Infect Dis*. 2007;45S:39–44.
3. Blanton LS. The rickettsioses: a practical update. *Infect Dis Clin North Am*. 2019;33:213–229.
4. Sahni A, Fang R, Sahni SK, Walker DH. Pathogenesis of rickettsial diseases: pathogenic and immune mechanisms of an endotheliotropic infection. *Annu Rev Pathol*. 2019;14:127–152.
5. Helmick CG, Bernard KW, D'Angelo LJ. Rocky Mountain spotted fever: clinical, laboratory, and epidemiological features of 262 cases. *J Infect Dis*. 1984;150:480–488.
6. Raoult D, Ndihokubwayo JB, Tissot-Dupont H, et al. Outbreak of epidemic typhus associated with trench fever in Burundi. *Lancet*. 1998;353:353–358.

Downloaded for Anonymous User (n/a) at Egyptian Knowledge Bank from ClinicalKey.com by Elsevier on March 10, 2024. For personal use only. No other uses without permission. Copyright ©2024. Elsevier Inc. All rights reserved.